

Congenital Eventration of Diaphragm Presenting in Adults: A Rare Clinical Scenario

Muhammad Muddassar Shafiq, Ahmad Kaleem, Talat Waseem

IMPORTANCE Eventration of diaphragm (ED) is defined as abnormal elevation of hemi-diaphragm. It may have congenital or acquired cause. Diaphragmatic eventration is rare and has incidence of <0.05%, being more common in males. A rare case of congenital diaphragmatic eventration is presented here. A 42 years old male presented with history of intermittent dyspnea and occasional epigastric discomfort. On routine physical examination, bowel sounds and decreased breath sounds were audible in left infra-axillary and left infra-scapular areas. Imaging modalities showed elevation of diaphragm, which was confirmed on CT Scan. We used thoracotomy approach for plication. Post-operatively patient suffered from left lung atelectasis for which the patient was managed conservatively. Patient was discharged after 1 week of hospital stay after having significant functional improvement.

KEY WORDS Eventration of Diaphragm, Adults, Diaphragmatic hernia, Surgical treatment

HOW TO CITE Shafiq MM, Kaleem A, Waseem T. Congenital Eventration of Diaphragm Presenting in Adults: A Rare Clinical Scenario. Archives of Surgical Research. 2021, 2 (2):66-69. <https://doi.org/10.48111/2021.02.11>

Case Report

Author Affiliations: Author affiliations are listed at the end of this article.

Corresponding Author: Mr Talat Waseem FRCS Eng, FACS, Consultant Surgeon Shalamar Medical & Dental College, Lahore twaseem@gmail.com 092-333-8078705 <https://doi.org/10.48111/2021.02.11>

Diaphragmatic eventration refers to an abnormal elevation of muscular part of all or portion of hemidiaphragm, without breach in its continuity, maintaining normal attachments to the sternum ribs and dorsolumbar spine.¹ It may be congenital or acquired. Acquired form has etiology of phrenic nerve injury and idiopathic.² It has incidence of 1:10,000 in adults, being more common in males, unilateral and left sided generally, with associations of anomalies like wandering spleen.³ Diagnosis is usually incidental since patients are often asymptomatic or develop mild symptoms. In symptomatic cases, presentation can be either dyspnea, palpitations, chest pain or non-specific GI symptoms like dyspepsia.⁴ Physical examination findings reflect decreased air entry in the lower part of involved hemithorax and possible resonance to percussion with audible bowel sounds in chest. Radiological diagnosis can be made on chest X-ray with incidental finding of elevated hemidiaphragm most of the time. In cases of doubt, thin section CT scan and MRI can be used. Ultrasound, fluoroscopy, and contrast GI studies can be used to check for complications.⁵ Accurate and timely diagnosis and management of diaphragmatic eventration is important in preventing morbidity and mortality.⁶ Plication of symptomatic diaphragmatic eventration has been shown to provide significant benefit. Plication of defect can be done using various approaches such as thoracotomy, laparotomy, thoracoscopy or laparoscopy.⁷ Thoracotomy approach has had reported improved rates of pulmonary function variables.⁸

CASE REPORT

A 42-year-old male presented with 2-month history of intermittent dyspnea and occasional epigastric discomfort. On routine physical examination, bowel sounds, and decreased breath sounds were audible in left infra-axillary and left infra-scapular areas. Right sided chest examination was unremarkable. Rest of his clinical examination was unremarkable. On X-ray chest, raised dome of diaphragm with regular contours and bowel loops were seen on left side, and mediastinal shift was seen towards right side. There was no blunting of costophrenic angles. The patient had no history of any congenital anomaly or any prolonged hospital admission in childhood especially with worsening dyspnea. He had no history of thoracoabdominal trauma, cardiac, head and neck surgery, neoplasm, orthopedic procedure fever and myalgias with anorexia. There was no history of pain on back of neck with tingling numbness or weakness of upper limbs and fever. He had no history of neck trauma, surgery, orthopedic intervention radiotherapy to neck, anesthesia to neck or orthopedic procedures to neck and shoulder. He had no history of recurrent cough with sputum or any catheter insertion in neck and chest. Rest of his systemic history was unremarkable. The patient had undergone admission to a public hospital on account of worsening dyspnea and was managed conservatively two months before coming to us. He had complaints of dyspepsia as well. We did a CT chest on this patient which confirmed diagnosis of eventration of diaphragm with no

evidence of diaphragmatic hernia. His routine laboratory tests were unremarkable. His ABG's revealed respiratory acidosis. His Pulmonary function tests reflected a moderate restrictive pattern with FEV1 being 61 % of predicted and FVC being 63% of predicted. Plication of left dome of diaphragm was done through thoracotomy approach under general anesthesia. We did double layered plication with running prolene sutures in first layer strengthened by

interrupted non-absorbable pledgeted sutures in second layer. Patient was monitored post-operatively in ICU. Post-operatively chest X-ray showed left diaphragm at normal anatomical position. However, mild basal atelectasis of left lung was seen and managed with deep breathing exercises and incentive spirometry. Patient was successfully discharged after 1 week of hospital stay. Patient is on regular follow-up and has functionally improved.

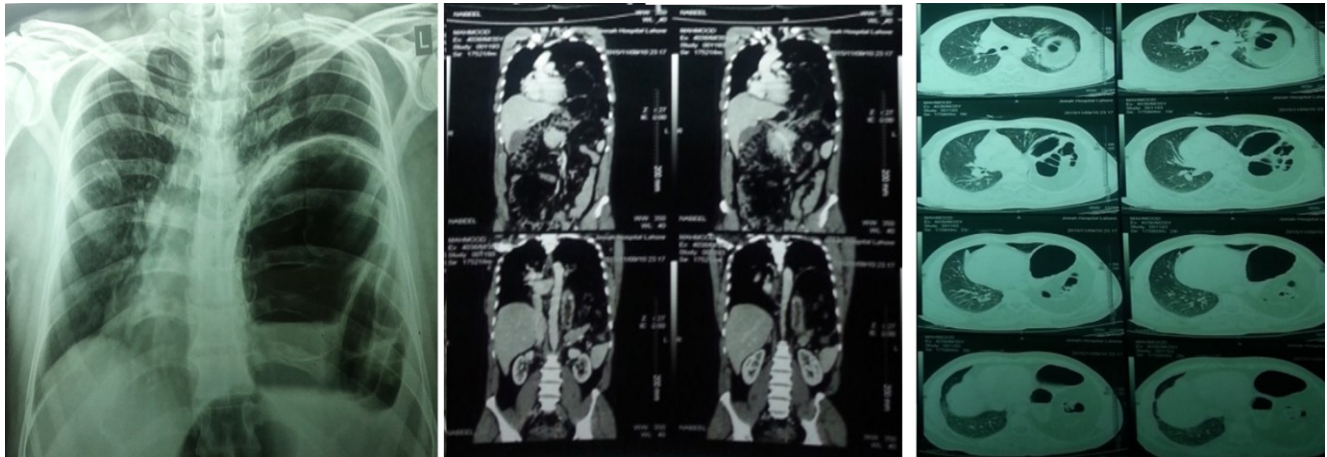


Figure 1: X-ray Chest and CT scan showing eventration of diaphragm. The affected hemidiaphragm is elevated in the shown chest X-ray with regular contours and no blunting of costophrenic angles. Atelectasis, mediastinal deviation, and bowel loops can be observed.

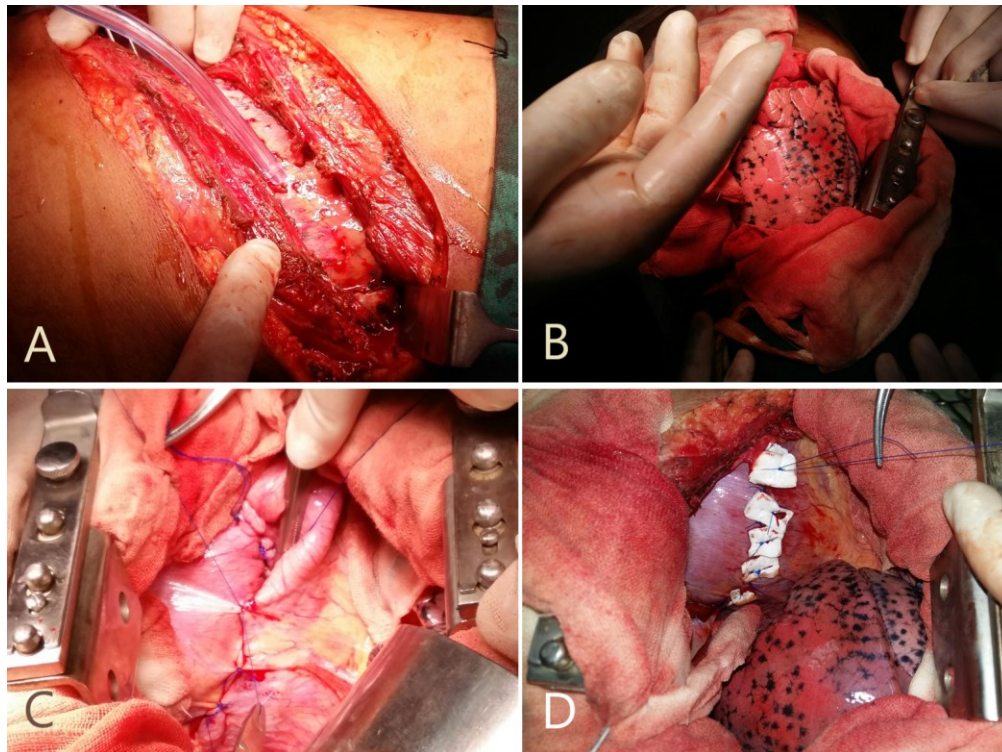


Figure 2: Postero-lateral Thoracotomy (A), Exposed Lung Parenchyma (B), Diaphragmatic Repair with running sutures (C) which have been reinforced by pledgeted sutures (D).

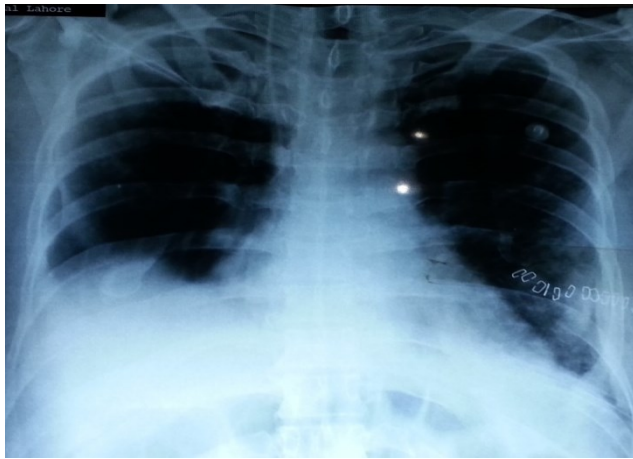


Figure 3: Postoperative Chest X-ray following repair for Diaphragmatic Eventration

DISCUSSION

Diaphragmatic eventration in its spectrum being congenital or acquired has reported incidence of <0.05% with male preponderance. The presentation range varies from asymptomatic, minimal symptoms to life threatening features with predominantly respiratory and GI complaints.⁹ They have had reported genetic associations with Poland and wandering spleen syndromes¹⁰ The symptomatology with advancing age correlates with constipation, increased stiffness of chest wall and changes in heart and lungs. On the whole, factors which push the diaphragm further up into the thoracic cavity worsen the symptoms.¹¹ Unilateral diaphragmatic dysfunction can compromise ventilatory function by 25% and if dyspnea which is the most common complaint progresses, it warrants plication of diaphragm to preclude worsening respiratory function.¹²

ARTICLE INFORMATION Accepted for Publication: June 6, 2021 Published Online: June 29, 2021.

<https://doi.org/10.48111/2021.03.11>

Open Access: This is an open access article distributed under the terms of the CC-BY License. © 2021 Waseem et al ASR.

Author Affiliations: Department of Surgery Shalamar Medical & Dental College Lahore, Pakistan

Declaration of Consent: The authors certify that they have obtained all appropriate consent required from the patient.

Financial Support and Sponsorship: Nil.

Conflicts of Interest: There are no conflicts of interest

REFERENCES

1. Das JC, Hasan SH, Bhuiyan AH, Paul N, Faisal MA, Roy DK, Chowdhury N, Ghosh N, Rashid MH. Congenital Eventration of Diaphragm Presenting As Diaphragmatic Hernia: A Case Report. *Mymensingh Med J.* 2019 Oct;28(4):952-956. PMID: 31599268.
2. Maish MS. The diaphragm. *Surg Clin North Am.* 2010 Oct;90(5):955-68. doi: 10.1016/j.suc.2010.07.005. PMID: 20955877.
3. Mehrotra AK, Vaishnav K, Gupta PR, Khublani TK, Anupam, Soni S, Feroz A. Eventration of the right hemidiaphragm with multiple associations: A rare presentation. *Lung India.* 2014 Oct;31(4):421-2. doi: 10.4103/0970-2113.142098. PMID: 25378860; PMCID: PMC4220334
4. Mouroux J, Venissac N, Leo F, Alifano M, Guillot F. Surgical treatment of diaphragmatic eventration using video-assisted thoracic surgery: a prospective study. *Ann Thorac Surg.* 2005 Jan;79(1):308-12. doi: 10.1016/j.athoracsur.2004.06.050. PMID: 15620964.
5. Makwana K, Pendse M. Complete eventration of right hemidiaphragm: A rare presentation. *J Family Med Prim Care.* 2017 Oct-Dec;6(4):870-872. doi: 10.4103/jfmpc.jfmpc_283_17. PMID: 29564282; PMCID: PMC5848417.
6. Patel PR, Bechmann S. Elevated Hemidiaphragm. 2020 Dec 21. In: StatPearls [Internet]. Treasure Island (FL): StatPearls Publishing; 2021 Jan-. PMID: 32644681.
7. Groth SS, Andrade RS. Diaphragmatic eventration. *Thorac Surg Clin.* 2009 Nov;19(4):511-9. doi: 10.1016/j.thorsurg.2009.08.003. PMID: 20112634.
8. Özkan S, Yazici Ü, Aydın E, Karaoğlanoğlu N. Is surgical plication necessary in diaphragm eventration? *Asian J Surg.* 2016 Apr;39(2):59-65. doi: 10.1016/j.asjsur.2015.05.003. PMID: 26117205.

It is important to delineate symptomatic diaphragmatic eventration from diaphragmatic hernia with and without defect, because congenital diaphragmatic eventration and hernia without defect although have similar outcomes and better survival rates than the patients with a hernia having a true defect, the duration of oxygen supplementation at 30 days and recurrence rates are higher in the former group.¹³ This could be due to increased utilization of multiple techniques from open to minimally invasive with varied plication patterns depending upon surgeon expertise. If the eventration is asymptomatic, we can adopt a wait and see policy. If the symptoms are present and diagnosis is established clinically, radiologically and by functional tests like ultrasound, and fluoroscopy, a period of observation of 6-12 months can be carried out before surgical plication by open or minimally invasive technique is deemed necessary.¹⁴ Classic plication of eventration with posterolateral thoracotomy is a safe option and caters for the concept of keeping diaphragm as taut as possible which is not accurately possible with the minimum invasive techniques in which the tactile feedback is less.¹⁵ Out of multiple techniques used to make the diaphragm tight, accordion technique and double breasting technique have been commonly used. The basic idea is to improve pulmonary function and produce better patient outcomes.¹⁶

CONCLUSION

To conclude, congenital diaphragmatic eventration is a rare occurrence but can be deadly if it remains undiagnosed. Therefore, high index of suspicion is required while interpreting symptomatology and evaluating extremely valuable chest x rays to give us the right direction for diagnosing such diagnostic dilemmas. A simple plication can indeed save lives in diaphragmatic eventration patients.

9. Agarwal AK, Lone NA. Diaphragm Eventration. 2021 Feb 5. In: StatPearls [Internet]. Treasure Island (FL): StatPearls Publishing; 2021 Jan-. PMID: 32809332.
10. Kulkarni ML, Sneharoopa B, Vani HN, Nawaz S, Kannan B, Kulkarni PM. Eventration of the diaphragm and associations. *Indian J Pediatr.* 2007 Feb;74(2):202-5. doi: 10.1007/s12098-007-0018-x. PMID: 17337837.
11. CHRISTENSEN P. Eventration of the diaphragm. *Thorax.* 1959 Dec;14(4):311-9. doi: 10.1136/thx.14.4.311. PMID: 13810104; PMCID: PMC1018519.
12. Moon SW, Wang YP, Kim YW, Shim SB, Jin W. Thoracoscopic plication of diaphragmatic eventration using endostaplers. *Ann Thorac Surg.* 2000 Jul;70(1):299-300. doi: 10.1016/s0003-4975(00)01385-0. PMID: 10921734.
13. Heiwegen K, van Heijst AF, Daniels-Scharbatke H, van Peperstraten MC, de Blaauw I, Botden SM. Congenital diaphragmatic eventration and hernia sac compared to CDH with true defects: a retrospective cohort study. *European journal of pediatrics.* 2020 Jan 22:1-9.
14. Ricoy J, Rodríguez-Núñez N, Álvarez-Dobaño JM, Toubes ME, Riveiro V, Valdés L. Diaphragmatic dysfunction. *Pulmonology.* 2019 Jul-Aug;25(4):223-235. doi: 10.1016/j.pulmoe.2018.10.008. Epub 2018 Dec 1. PMID: 30509855.
15. Calvino P, Bastos C, Bernardo JE, Eugénio L, Antunes MJ. Diaphragmatic eventration: long-term follow-up and results of open-chest plication. *Eur J Cardiothorac Surg.* 2009 Nov;36(5):883-7. doi: 10.1016/j.ejcts.2009.05.037. Epub 2009 Jul 24. PMID: 19632127.
16. Evman S, Tezel C, Vayvada M, Kanbur S, Urek S, Baysungur V, Yalçinkaya I. Comparison of Mid-Term Clinical Outcomes of Different Surgical Approaches in Symptomatic Diaphragmatic Eventration. *Ann Thorac Cardiovasc Surg.* 2016 Aug 23;22(4):224-9. doi: 10.5761/atcs.aa.16-00018. Epub 2016 Apr 14. PMID: 27076066; PMCID: PMC5045849.