

Pre-Operative Parathyroid Gland Localization in Primary Hyperparathyroidism: A Systematic Literature Review

Hira Ashraf, Muhammad Muddassar Shafiq, Safia Zahir Ahmed, Talat Waseem

INTRODUCTION Primary hyperparathyroidism is amongst the most common endocrine disorders. Parathyroidectomy is the only definitive cure. Traditionally, bilateral neck exploration was performed; however, now surgeons largely prefer minimally invasive parathyroidectomy. Pre-operative localization aids in selecting candidates for minimally invasive parathyroidectomy. Non-invasive imaging modalities commonly used include ultrasound, sestamibi scintigraphy, 4-D CT, MRI, PET and PET/CT.

OBJECTIVE The objective of this literature review is to evaluate technique, accuracy, advantages and disadvantages of the non-invasive imaging modalities in order to propose algorithm in de novo and re-operative cases.

METHODS This systematic review is written according to the PRISMA (Preferred Reporting Items for Systematic Reviews and Meta-analysis) guidelines. A comprehensive literature search of PubMed/MEDLINE and Google Scholar was performed using search terms "primary hyperparathyroidism" OR "parathyroid adenoma" AND "pre-operative localization" OR "pre-surgical localization". 195 papers were identified through literature search. Following removal of 19 duplicates, titles and abstracts of 176 papers were reviewed. After thorough analysis, 41 papers were included in this literature review.

RESULTS Minimally invasive parathyroidectomy requires accurate pre-operative localization. Surgeons prefer two concordant imaging techniques prior to minimally invasive parathyroidectomy. In de novo cases ultrasound and sestamibi scintigraphy are the commonly employed techniques. However, 4-D CT has shown superior performance. In re-operative cases ultrasound and 4-D CT are used as first line modalities. MRI, PET or PET/CT are preferred prior to invasive methods of localization in inconclusive first line imaging of re-operative cases.

CONCLUSION Determination of accuracy of different imaging techniques can help select candidates for targeted tissue dissection with smaller incision and improved surgical outcome. However, devising a single algorithm for pre-operative localization using non-invasive imaging techniques remains undetermined.

KEYWORDS Primary Hyperparathyroidism, Ultrasound, Sestamibi Scintigraphy, Computed Tomography (CT), Magnetic Resonance Imaging (MRI), Positron Emission Tomography (PET).

HOW TO CITE: Ashraf H, Shafiq MM, Ahmed SZ, Waseem T. Pre-Operative Parathyroid Gland Localization in Primary Hyperparathyroidism: A Systematic Literature Review. *Archives of Surgical Research*. 2020;1(1):29-39. <https://doi.org/10.48111/2020.01.05>

Systematic Literature Review

Author Affiliations: Author affiliations are listed at the end of this article.

Corresponding Author:

Dr. Talat Waseem FRCS Eng, FACS

Consultant Surgeon
Shalamar Medical & Dental
College, Lahore

twaseem@gmail.com

<https://doi.org/10.48111/2020.01.05>

P rimary hyperparathyroidism is known as the most common cause of hypercalcemia and third most common cause of endocrine disorders, first two being diabetes mellitus and hyperthyroidism¹. Its incidence increases with age and has 2 to 3 times greater predisposition in women than men². Causative factors include single benign adenoma (85-90%), multiglandular hyperplasia (6%), double adenoma (4%) and carcinoma (<1%)³.

Surgical excision of abnormal tissue is the recommended treatment of choice for primary hyperparathyroidism,

parathyroid carcinoma, persistent primary hyperparathyroidism and recurrent primary hyperparathyroidism^{4,5}. However, parathyroid surgeries are stalled because of problems with accurate localization, increased risk of intraoperative bleeding, injury to recurrent laryngeal nerve and transient or permanent hypoparathyroidism⁶. Anatomic position of parathyroid glands is not fixed which hinders the accurate localization of glands. In vast majority there are four glands, however, they are also seen in excess or less number. Superior glands are derived from fourth branchial pouch and are more

consistent in their position than lower glands, which develop from third branchial pouch and travel greater distance^{7,8}. Ectopic glands, which may lie in retroesophageal position, retropharyngeal position, mediastinum, thymus, thyro-thymic ligament and carotid sheath, further increase the risk of surgical complications.

Traditionally, bilateral neck exploration was performed but surgeons now prefer minimally invasive parathyroidectomy in selected cases. Minimally invasive parathyroidectomy has become the preferred procedure as it involves targeted tissue dissection. It has shorter procedure time, shorter stay in hospital, lower cost, lesser surgical complications and better cosmetic result. Minimally invasive parathyroidectomy can also be effectively performed with locoregional and intravenous sedation^{9,10}.

Pre-operative localization is recommended for cases with biochemically proven primary hyperparathyroidism. Pre-operative localization of hyperfunctioning parathyroid glands aids in selecting the candidates eligible for minimally invasive parathyroidectomy and in determining presence of ectopic glands, thyroid neoplasia, persistent or recurrent disease. Precise localization increases success rate of parathyroidectomy while inconclusive localization is reported a risk factor for persistent disease⁶.

In this article non-invasive imaging modalities used for pre-operative localization of parathyroid glands in primary hyperparathyroidism are reviewed. The accuracy of imaging modalities in de novo, re-operative, persistent and recurrent cases along with their advantages and disadvantages are summarized in this review using the up to date data available.

METHODS

This literature review is written according to the PRISMA (Preferred Reporting Items for Systematic Reviews and Meta-analysis) guidelines with objective of analyzing data available for pre-operative localization of parathyroid glands in primary hyperparathyroidism.

Search strategy: A comprehensive computer literature search of PubMed/MEDLINE and Google Scholar was performed. The search algorithm was based on combination of terms: "primary hyperparathyroidism" OR "parathyroid adenoma" AND "pre-operative localization" OR "pre-surgical localization". All the search papers were reviewed according to the selected search strategy. In addition, reference research papers were also included in this review to expand the search.

Inclusion of articles: 195 papers were identified using the computer literature search. Titles and abstracts of all the papers were reviewed using the inclusion and exclusion criteria. 19 papers were excluded for duplication, remaining 176 papers were reviewed and 41 papers related to the topic were included in this literature review. Full text versions of

the articles related to the topic were reviewed. No language, age or gender restriction was applied. All papers from the year 1996 to 2020 were included in the literature search. Exclusion criteria included duplicate papers, papers on animal studies, poster presentations, papers not related to the topic, papers on thyroid gland, papers on MEN syndrome or secondary and tertiary hyperparathyroidism. The article selection process is given in Diagram 1.

Data extraction and analysis: Thematic analysis of each eligible paper was done. Information about year of origin, author name, country of origin, method of study and theme identified was collected and coded. Metrics of diagnostic accuracy from each study were obtained which included sensitivity, pooled sensitivity and pooled positive predictive value (PPV). The themes identified through analysis of the data are given in Table 1.

Results: 195 papers were identified through comprehensive computer literature search. Titles and abstracts of 176 papers were reviewed following removal of duplicates. 41 papers related to the topic were included after thorough analysis. Recurrent themes were identified in the included papers and these themes are coded in Table 1.

FINDINGS

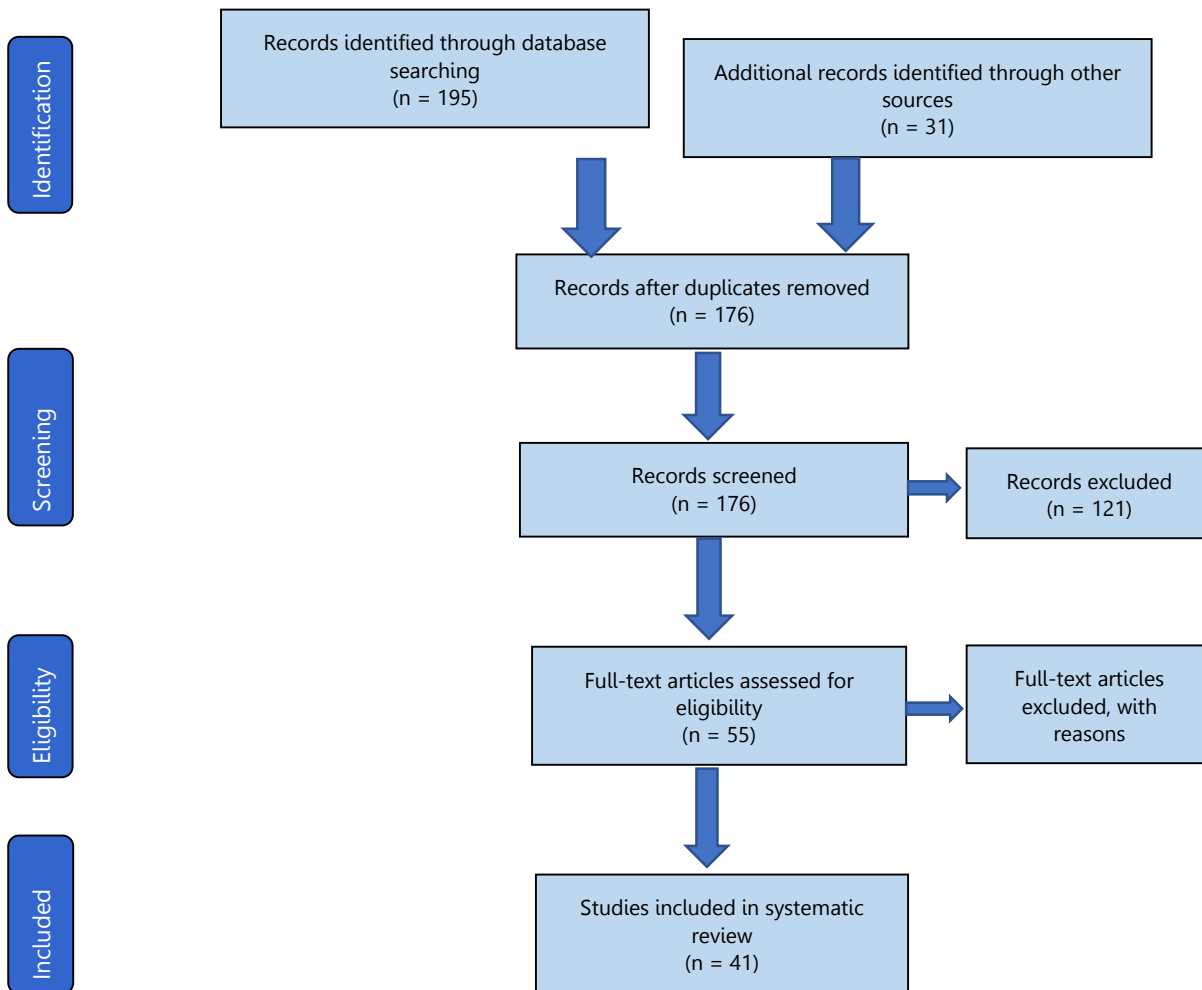
Ultrasound is the first line non-invasive imaging modality used for preoperative localization¹¹. Assessment of the anterior cervical region with a high frequency linear transducer is required. Patient lies in supine position with neck extended, special attention is paid to posterior and inferior thyroid margins¹². Normal glands are not detected by ultrasound. However, adenoma appears as ovoid, homogenous, hypoechoic and well-circumscribed mass in contrast with the thyroid tissue^{10,13}. Though, differentiation from calcification, cystic degeneration, hemorrhage and fibrosis should be kept in mind for accurate localization¹⁴. Color doppler demonstrates the presence of polar feeding vessel or peripheral vascularity of the adenomatous mass, which differentiates adenoma from lymph node¹⁵. Ultrasound also guides fine needle aspiration of parathyroid lesions. The need for surgery in thyroid lesions is reduced from 30% to 6% by obtaining fine needle biopsy through ultrasound¹⁶.

Sensitivity of ultrasound in pre-operative localization is 79% for solitary adenomas, 34.9% for multi-gland hyperplasia and 16.2% for double adenomas³. In de novo patient's ultrasound has a pooled sensitivity of 76% and pooled positive predictive value (PPV) of 93%¹⁷. Lee et al. showed that ultrasound has highest sensitivity of 91.5% regarding pre-operative localization¹⁸. With contrast the sensitivity is reported greater than 95% in certain studies¹⁹. However, the sensitivity of ultrasound in re-operative cases decreases and is reported between 54%-68% in persistent or recurrent disease and nearly 40% in cases with multi-gland disease^{20,21}.

Ultrasound is the preferred first line modality as it is inexpensive, readily available and radiation free. Ultrasound also gives good anatomic resolution ¹⁰. It aids in concurrent evaluation of thyroid neoplasia and fine needle aspiration of parathyroid tissue. However, its effectiveness is highly operator dependent ¹². It has inability to assess ectopic glands located in mediastinum, tracheoesophageal groove,

retroesophageal position and retro-clavicular position ¹¹. Ultrasound is insensitive for enlarged glands and intrathyroidal lesions ²². Ultrasound has reduced sensitivity for multi-gland parathyroid disease and concurrent thyroid nodules ²³. Ultrasound fails to localize adenomas in obese patients ¹¹.

Figure 1: Prisma Flowchart- Article selection process through computer literature search and analysis:



Parathyroid scintigraphy is another first line imaging modality used for pre-operative localization. Tc99m sestamibi is the principal radiotracer used for localization of abnormal parathyroid tissue ¹¹. It accumulates in parathyroid glands and thyroid gland depending upon their metabolic activity and blood flow ²⁴. It typically accumulates in mitochondria rich cells of hyperfunctioning parathyroid glands ²⁵. Hence, its sensitivity depends on oxyphil cell density, number of mitochondria, co-existing neck pathology and solid or cystic nature of gland ²⁶.

Several scintigraphy protocols have been proposed but the most widely employed is single-isotope dual-phase

scintigraphy ²⁷. It doesn't require patient preparation ²⁸. Following administration of radiotracer, early and late phase planar images of neck and mediastinum are obtained at 10-30 mins and 90-180 mins respectively ^{24,28}. Radiotracer rapidly accumulates in both parathyroid and thyroid tissue following administration. However, parathyroid adenoma appears as focus of accumulation on early images and intensifies on delayed images because radiotracer washes out of 60%-85% parathyroid adenomas more gradually than

normal parathyroid and thyroid tissue ¹⁰. The remaining 15%-40% adenomas exhibiting rapid wash-out are difficult to diagnose ²⁸.

Table 1: Studies included in the systematic literature review and their corresponding outcomes

Year	Author	Country	Research Method	Study Outcome
1996	Mazzeo (Mazzeo et al, 1996)	US	Ultrasound and Scintigraphy imaging used in 73 cases as first line	Ultrasound and scintigraphy have comparable sensitivity in detecting parathyroid lesions when used as first line
1999	Ishibashi (Ishibashi et al, 1999)	Japan	3-D CT and Scintigraphy used in 2 cases with ectopic parathyroid gland	Scintigraphy detected ectopic glands in both patients. 3-D CT aided in surgical planning with anatomic resolution
2003	Kaczirek (Kaczirek et al, 2003)	Austria	99m Tc-sestamibi/X-ray-CT used in 4 cases with ectopic parathyroid glands	99m Tc-sestamibi/X-ray-CT localized ectopic glands in all 4 cases
2004	Timm (Timm et al, 2004)	Germany	Prospective study of 40 cases of primary hyperparathyroidism 21 cases had minimally invasive parathyroidectomy 7 cases had bilateral neck exploration 12 cases had unilateral parathyroid exploration and thyroid resection	With accurate pre-operative localization 95% patients can be scheduled for appropriate surgical approach.
2005	Beggs (Beggs & Hain 2005)	UK	Retrospective study after 11C-methionine PET scanning in 51 cases of hyperparathyroidism with other failed imaging techniques	11C-methionine PET showed high accuracy (88%) in detecting parathyroid adenomas
2006	Malinvaud (Malinvaud et al, 2006)	France	Retrospective study of 51 cases for treatment with pre-operative localization with ultrasound in 51 and sestamibi scan in 49 cases	Accurate pre-operative localization allows targeted surgery with shorter hospital stay, shorter procedure duration, lesser complications and cost effectiveness
2007	Singh (Singh & Krishna 2007)	India	Retrospective study of 28 cases to determine role of scintigraphy in parathyroid adenoma detection	Scintigraphy exhibits high sensitivity in parathyroid adenoma detection and can be used as first line imaging
2008	Bybel (Bybel et al, 2008)	Canada	Narrative review	SPECT/CT provides anatomic resolution for localization in cases where SPECT fails.
2011	Evangelista (Evangelista et al, 2011)	Italy	Retrospective study of 5 cases with parathyroid carcinoma using fluorodeoxyglucose PET/CT at initial staging, restaging and post-surgical evaluation	PET/CT has high sensitivity for parathyroid carcinoma
2012	Saengsuda	Thailand	Retrospective study of 71 cases (to assess scintigraphy accuracy) with hyperparathyroidism who underwent surgery. 18 cases with primary hyperparathyroidism and 53 cases with secondary-tertiary hyperparathyroidism	Scintigraphy has sensitivity and accuracy for localization in primary hyperparathyroidism. Scintigraphy cannot be classified as essential prerequisite in secondary tertiary hyperparathyroidism and multi-gland disease prior to surgery.
2012	Kim (Kim et al, 2012)	Japan	Retrospective study of 31 cases with hyperparathyroidism to assess efficacy of 99m-Tc sestamibi SPECT/CT for minimally invasive parathyroidectomy	99m-Tc sestamibi SPECT/CT can detect parathyroid adenomas and multi-gland disease missed by conventional imaging and SPECT.
2012	Treglia (Treglia et al, 2012)	Switzerland	Meta-analysis for detection rate of 99m-Tc sestamibi SPECT/CT	99m-Tc sestamibi SPECT/CT has sensitivity for localization in primary hyperparathyroidism
2014	Philippon (Philippon et al, 2014)	France	Retrospective study of 182 patients treated for primary hyperparathyroidism with bilateral neck exploration	Discordant and negative imaging results are seen in both multi-gland disease and single adenoma.

2014	Exposito (Exposito et al, 2014)	Spain	Case report	99m Tc-scintigraphy helps in localization of intrathyroidal adenoma.
2014	Keidar (Keidar et al, 2014)	Israel	Retrospective study of 36 cases with primary hyperparathyroidism to assess accuracy of Tc-99m scintigraphy SPECT/CT	Tc99m-scintigraphy SPECT/CT has an accuracy of 83%
2015	Barczynski (Barczynski et al, 2015)	European society of endocrine surgeons	Review article	Negative pre-localization studies are highly predictive of multi-gland disease. Pre-operative localization of multi-gland disease is challenging
2015	Ozkaya (Ozkaya et al, 2015)	Turkey	Retrospective study of 39 cases of primary hyperparathyroidism to evaluate accuracy of conventional imaging techniques	Sensitivity and PPV of ultrasound and scintigraphy when combined is greater than individual imaging. Concurrent application is more successful in detection of enlarged glands
2016	Thanseer (Thanseer et al, 2016)	India	Case report	18-F-fluoromethylcholine PET/CT localized the ectopic parathyroid adenoma missed by ultrasound and scintigraphy imaging.
2017	Reid (Reid et al, 2017)	UK	Retrospective cohort study	Ultrasound is highly accurate in lateralizing parathyroid adenomas. 18-fluorocholine PET/CT maybe helpful in localization when conventional imaging fails
2017	Ozderya (Ozderya et al, 2017)	Turkey	Retrospective study of 65 patients who underwent ultrasound guided fine needle aspiration	Ultrasound guided fine needle aspiration can improve accuracy. Metastatic lymph node and thyroid nodule can give false positive with 99m technetium scintigraphy.
2017	Al-Githmi	Saudi Arabia	Retrospective study	Minimally invasive parathyroidectomy has better cosmetic result with shorter hospital stay, cost effectiveness and lesser complications
2017	Raruenrom (Raruenrom et al, 2017)	Thailand	Retrospective study	Dual tracer scintigraphy has higher accuracy than dual phase scintigraphy. SPECT and SPECT/CT have higher diagnostic accuracy
2018	Grimaldi (Grimaldi et al, 2018)	France (EJNMMI)	Prospective study of 46 patients for pre-surgical evaluation of hyperparathyroidism by 18-F-fluoromethylcholine PET/CT	18-F-fluoromethylcholine PET/CT has high sensitivity and specificity for localization. it has added value in inconclusive imaging, re-operative cases and multi-gland disease.
2018	Kim (Kim et al, 2018)	South Korea	Systematic review and metanalysis on diagnostic performance of 18-F-fluoromethylcholine PET/CT	18-F-fluoromethylcholine PET/CT has high sensitivity and specificity for localization in primary hyperparathyroidism but requires large multicenter studies to establish its beneficial role.
2018	Tay (Tay et al, 2018)	US	Retrospective study of 138 patients	Sestamibi scintigraphy readily detected ectopic glands which more commonly arise from inferior glands. Sestamibi scintigraphy has high accuracy for localization and lateralization
2018	Thimmappa (Thimmappa et al, 2018)	US	Retrospective study	Ultrasound has better predictive value than scintigraphy. Pre-operatively, ultrasound and scintigraphy are the two preferred concordant imaging techniques
2018	Zajickova (Zajickova, Zogala & Kubinyi, 2018)	Slovakia	Retrospective study of patients with previous negative or discordant imaging	18-F-Fluoromethylcholine PET/CT has a sensitivity of 92%. It has high sensitivity for small, hyperplastic and multiglandular disease
2018	Bossert (Bossert et al, 2018)	Italy	Retrospective cohort study of 34 cases	18-F-Fluoromethylcholine PET/CT can be recommended as first line imaging but requires large scale studies and it has high sensitivity for small glands. It can detect disease in early stages.
2018	Piccardo (Piccardo et al, 2018)	Italy (EJNMMI)	Retrospective study of 44 cases of primary hyperparathyroidism with inconclusive first line imaging	18-F-fluoromethylcholine PET/4D contrast enhanced CT is the most accurate second line imaging in patients with negative or inconclusive first line techniques
2018	Treglia (Treglia et al, 2018)	Switzerland (EJNMMI)	Systematic review and meta-analysis	PET/CT has high accuracy for localization in primary hyperparathyroidism. It requires prospective studies and cost-effective analysis before its recommendation for routine use
2019	Uludag, 2019	Turkey	Literature review	In primary hyperparathyroidism localization can be done in 80-90% using non-invasive imaging. Ultrasound and scintigraphy are first line imaging techniques. In negative or inconclusive imaging 4-D CT or PET/CT can be done.

2019	Miguel (Miguel et al, 2019)	Spain	Literature review	Dual-tracer scintigraphy is preferred in cases with concomitant thyroid disorder. PET/CT or MRI or CT are preferred in cases with inconclusive first line imaging techniques which is usually the combination of ultrasound and scintigraphy.
2019	Assante (Assante et al, 2019)	Italy	Retrospective study of 46 cases with primary hyperparathyroidism and inconclusive ultrasound, to compare SPECT/CT and scintigraphy	Combination of anatomic and functional information has led to higher sensitivity and specificity of SPECT/CT than planar scintigraphy
2019	Boccalatte (Boccalatte, Higuera & Gomez, 2019)	Argentina (JAMA)	Systematic review	18-F-fluoromethylcholine PET/CT is effective imaging technique in difficult cases and inconclusive first line imaging
2020	Parikh (Parikh, Grogan & Moron, 2020)	US	Review article	First line modalities in re-operative cases should constitute both ultrasound and 4-D CT. In re-operative cases with negative first line imaging PET/CT or MRI should be considered prior to invasive techniques
2020	Hindie (Hindie, Urena-Torres & Taieb, 2020)	France	Literature review	Re-operative cases require combination of imaging techniques. 4-D CT and MRI have high accuracy for ectopic glands
2020	Maïssin (Maïssin et al, 2020)	France	Retrospective study of 273 patients who underwent ultrasound and 99m-Tc sestamibi scintigraphy	The sensitivity and PPV of ultrasound and sestamibi scintigraphy is higher when used in combination than individual sensitivities and PPV
2020	Vazquez (Vazquez et al, 2020)	Spain	Prospective cohort study of 34 cases with primary hyperparathyroidism	PET/CT has higher accuracy in small adenoma, re-operative cases and hypocalcemia than gold standard techniques
2020	Evangelista (Evangelista et al, 2020)	Italy	Systematic literature review	18-F-fluoromethylcholine PET/CT has higher accuracy in detecting parathyroid adenoma than conventional ultrasound and SPECT
2020	Minhas (Minhas et al, 2020)	US	Retrospective study of 18 cases with primary hyperparathyroidism.	4-D CT has higher sensitivity and specificity than SPECT
2020	Morland (Morland et al, 2020)	France	Retrospective study of 47 cases who underwent 18-F-fluoromethylcholine PET/CT as second line imaging	Fluoromethylcholine PET/CT is a promising second line imaging. It requires large scale prospective studies

Sensitivity of sestamibi scintigraphy in pre-operative localization is 88.4% for solitary adenomas, 44.5% for multi-gland hyperplasia and 30% for double adenomas³. Sestamibi scintigraphy has a pooled sensitivity of 63% and pooled PPV of 90%²⁹. However, Lee et al. showed sestamibi has the lowest sensitivity of 56.1% regarding pre-operative localization¹⁸. Sensitivity of sestamibi scintigraphy in re-operative cases with persistent and recurrent disease is 53% to 74% and between 23% to 45% in multi-gland disease^{30,31}. Addition of SPECT/CT after the early, delayed or both planar images aids in surgical planning²⁸. Though many centers prefer SPECT imaging in early phase to detect rapid wash out adenomas³². It offers combination of a better anatomic visualization in 3 dimensions and improved contrast resolution for functional analysis into a single image²⁵. Addition of SPECT/CT aids in detection of ectopic glands, deep seated adenomas and relation of abnormal mass with adjacent structures¹⁰. SPECT acquisitions are not associated with additional radiation exposure; however, CT is associated with increased radiation exposure²⁸. Single-isotope dual-phase SPECT has pooled sensitivity of 79% and pooled PPV of 91%¹⁷. Meta-analysis of 18 studies showed

single-isotope dual-phase SPECT/CT has pooled sensitivity of 84% and pooled PPV of 95%²⁹.

Single-isotope dual-phase scintigraphy is preferred as first line modality because of its ability to detect ectopic and far posterior glands. Its effectiveness is independent of operator. It gives both anatomic and functional information with SPECT/CT^{10,11}. However, it is associated with radiation exposure, long imaging duration, motion degradation and poor anatomic resolution. It is insensitive for rapid wash out adenomas and normal parathyroid tissue. It has reduced sensitivity for multi-gland disease and patients taking calcium channel blockers (decreased sestamibi uptake)³³. It fails to localize hyperplastic glands. Delayed wash out from thyroid nodules and enlarged cervical lymph nodes gives false positive results²⁵.

An alternate scintigraphy protocol is dual-isotope single-phase technique. In this technique sestamibi radiotracer taken up by both parathyroid and thyroid gland and iodine-123 or technetium Tc99m pertechnetate radiotracer taken up specifically by thyroid gland are used³⁴. Images are sequentially acquired. First image is acquired after administration of thyroid specific radiotracer and second image is acquired following administration of radiotracer

taken up by both thyroid and parathyroid gland. Abnormal parathyroid tissue is identified by visual comparison of the two images or via digital subtraction²². Dual-isotope single-phase technique is preferred in a European study because of decreased possibility of false positive results with thyroid nodules and enhanced sensitivity for multi-gland disease²². However, it is associated with higher radiation exposure, requires patient preparation and depends on motion free images¹⁰.

4-D Computed Tomography (4-D CT) is more commonly used for pre-operative localization of cases with inconclusive first line imaging. However, its use is rapidly increasing with some employing it as first line modality. Several protocols are in use but the most common one involves 3 phase (non-contrast phase, arterial phase and venous phase) CT acquisition of neck and upper thorax³⁵. The four dimensions are axial, coronal, sagittal and time^{13,32}. Arterial and venous phase are acquired at 30 sec and 60 sec respectively following contrast administration. Attenuation exhibited by parathyroid adenomas in contrast with thyroid gland is lower in non-contrast phase, greater in arterial phase and lower in venous phase³⁶. Familiarity with mimicking lesions, such as calcification, cystic degeneration and fibrosis, is necessary for accurate localization³⁷.

In primary hyperparathyroidism 4-D CT has sensitivity range of 62%-92 and PPV range of 88%-94% when used as first line modality^{38,39}. When used as second line modality in inconclusive prior imaging it has sensitivity range of 67%-89% and PPV range of 65%-87%⁴⁰. In re-operative cases it has sensitivity of 93% for localization and 97% for lateralization^{41,42}. It has sensitivity range of 43%-69% for accurate multi-gland disease localization^{43,44}. In re-operative setting 57%-75% of the lesions missed by 4-D CT are multi-gland disease⁴⁵. In addition, it is more accurate in lateralizing lesions with mild hypercalcemia and low weight glands than sestamibi scintigraphy³⁸.

4-D CT gives high-resolution spatial anatomic display which is helpful in re-operative cases for identifying important landmarks and surrounding structures¹¹. It is well suited in re-operative cases because its sensitivity in de novo and re-operative cases is comparable, unlike ultrasound and scintigraphy⁴⁶. Comparatively, it has superior performance in pre-operative localization of persistent and recurrent disease⁴⁷. 4-D CT enables minimally invasive parathyroidectomy in difficult re-operative cases because of its ability to differentiate unilateral and bilateral disease in up to 96% re-operative cases^{20,48}. It has relatively high sensitivity for multi-gland disease, ectopic glands, setting of mild hypercalcemia, mildly enlarged glands and patients with inconclusive first line imaging¹⁰. In addition, it has short imaging time. However, it is associated with increased radiation exposure and requires experienced radiologist³⁵.

Magnetic Resonance Imaging (MRI) is commonly used second line imaging modality parallel to 4-D CT for pre-operative localization of parathyroid glands¹³. Protocols of

conventional MRI include pre-contrast axial T1 and T2 weighted images and post-contrast T1 weighted images with fat saturation¹¹. On pre-contrast T1 and T2 weighted images and post-contrast T1 weighted images, parathyroid adenomas appear isointense, hyperintense and strongly enhancing to the muscle, respectively⁴⁹. Dynamic 4-D contrast enhanced (DCE) MRI is a multiphase modality based on the principle of hypervascularity of the parathyroid adenomas¹⁰. DCE MRI makes use of perfusion characteristics to differentiate parathyroid adenomas from mimicking lesions such as lymph nodes and thyroid tissue. Parathyroid adenomas show faster arterial enhancement and higher wash in and wash out compared with mimicking lesions⁵⁰. Conventional MRI has sensitivity of 91% for localization in primary hyperparathyroidism¹³. MRI increases localization sensitivity from 75% to 92% when used in combination with ultrasound and sestamibi scintigraphy⁴⁹. MRI has sensitivity of 82% in re-operative cases^{49,51}. In a research authors stated that MRI can be preferred to select candidates with parathyroid adenoma for minimally invasive parathyroidectomy. MRI could localize 2 out of 7 adenomas missed by ultrasound and 6 out of 8 adenomas missed with scintigraphy, however, combined use of MRI and ultrasound could detect all the cases of multi-gland disease and ectopic adenomas⁵². DCE MRI has sensitivity of 91% for parathyroid adenomas in unselected cases⁵⁰. DCE MRI has sensitivity of 90% for adenomas in re-operative cases⁴⁹.

MRI is not associated with radiation exposure unlike scintigraphy and 4-D CT, hence can be preferred in patients with contraindication to radiations. Its sensitivity in de novo and re-operative cases is comparable. When used as first line modality it shows significant sensitivity but its use in re-operative cases gives added benefit as accuracy of ultrasound and scintigraphy markedly suffer in such cases⁴⁹. However, in contrast to CT it is expensive, inaccessible and time consuming. It requires large sample investigations before establishing its significant role in cases with persistent and recurrent disease¹¹.

Positron Emission Tomography (PET) and Hybrid PET/CT is emerging as significant imaging modality in difficult parathyroid cases^{10 13}. It has gained popularity for consideration prior to invasive methods of localization in scheduled re-operative patients with persistent or recurrent disease³⁴. The radiotracers administered in this technique show particular avidity for metabolically active tissues such as parathyroid adenomas which appear as focal areas of uptake¹¹. Methionine is precursor amino acid for parathormone while choline is required for cell membrane synthesis^{53,54}. The investigated radiotracers used in this modality include 11C-methionine, 18F-fluorodeoxyglucose and 18F-fluoromethylcholine. This modality gives enhanced spatial anatomic resolution. Hybrid imaging with PET and low dose CT gives better anatomic resolution in addition to functional analysis.

¹¹C methionine PET has pooled sensitivity of 77% and pooled PPV of 98% for both de novo and re-operative patients ⁵⁵. ¹¹C methionine PET has a sensitivity range of 75%-88% in re-operative cases of primary hyperparathyroidism ⁵⁶⁻⁵⁸. Similarly, ¹⁸F-fluorodeoxyglucose PET has a sensitivity of 62% in re-operative cases ⁵⁹. ¹¹C-methionine PET/CT has a sensitivity of 61% in re-operative patients and this figure may be as low as 40% in difficult cases ⁶⁰. ¹⁸F-fluoromethylcholine PET/CT has sensitivities of 96 and 100% in persistent or recurrent disease ⁶¹. ¹⁸F-fluoromethylcholine PET/CT has sensitivity of 79% and PPV of 100% for multi-gland disease ⁶². In a meta-analysis of 11 studies ¹⁸F-fluoromethylcholine PET/CT has shown localization of 97% in patient-based and 94% in lesion-based analysis. This study stated that it could replace sestamibi scintigraphy in parathyroid imaging ⁶³. In addition, the combined use of ¹⁸F-fluorodeoxyglucose and ¹⁸F-fluoromethylcholine in PET/CT has demonstrated beneficial role for determining extent of primary disease, metastases and recurrence in parathyroid carcinoma ⁶⁴. ¹⁸F-fluoromethylcholine PET/CT gives better spatial resolution with shorter study time and lesser radiation exposure than SPECT/CT ⁶⁵. PET enables detection of small glands by giving better spatial and temporal resolution than SPECT ⁵⁵. In a study of 29 patients ¹⁸F-fluoromethylcholine PET/CT is seen to be more sensitive for parathyroid localization in re-operative cases than ultrasound, sestamibi scintigraphy and 4-D CT ⁶¹. However, PET/CT is expensive, infrequently used and requires larger samples to establish its role in localization in persistent and recurrent disease ¹¹. ¹⁸F-fluorocholine PET/CT usually fails to detect ectopic adenomas and hyperplastic glands ^{62,66}.

DISCUSSION

A universal shifting of practice from traditional bilateral neck exploration to unorthodox minimally invasive parathyroidectomy requires accurate preoperative localization. Pre-operative localization in primary hyperparathyroidism has enabled surgeons to perform procedure with smaller incision and targeted tissue dissection. Precise pre-operative localization is a predictor of success of parathyroidectomy. Moreover, precise localization in re-operative or persistent cases is crucial. Negative or discordant imaging can be a risk factor for operative failure, hence, requiring additional imaging modalities when first line techniques are inconclusive. Based on the data reviewed, ultrasound is the preferred first line modality as it has increased sensitivity and PPV for pre-operative localization. In addition, it is radiation free, readily available and cost effective. However, its sensitivity significantly reduces in re-operative cases and multi-gland disease. It is unable to detect ectopic glands. Sestamibi scintigraphy is another first line modality with high

sensitivity and PPV, but it requires radiologic expertise more than ultrasound and 4-D CT. In addition, it is expensive and associated with radiation exposure. It has reduced sensitivity in re-operative cases and multi-gland disease. However, addition of SPECT CT aids in detection of ectopic glands. Cost effectiveness and overall superior performance favors 4-D CT over sestamibi scintigraphy as second line imaging modality. The performance of 4-D CT in de novo and re-operative cases is comparable. 4-D CT has higher sensitivity in re-operative cases, multi-gland disease and cases with inconclusive first line imaging compared with ultrasound and sestamibi scintigraphy. MRI has comparable sensitivity in de novo and re-operative cases unlike ultrasound and sestamibi scintigraphy. MRI has high sensitivity for multi-gland disease and ectopic glands. However, it is expensive, time consuming and not readily available. PET/CT has beneficial role in parathyroid carcinoma as well as in detection of small glands and is seen to be more sensitive in re-operative cases than ultrasound, sestamibi scintigraphy and 4-D CT in certain studies. However, it is expensive and infrequently used. Both MRI and PET/CT require larger sample size to establish their beneficial role in persistent and recurrent disease.

Following biochemical diagnosis of hyperparathyroidism surgeons usually prefer two concordant imaging modalities prior to minimally invasive parathyroidectomy. Observation showed highest sensitivity of 95 % with ultrasound and CT combination and lowest of 88.3% with sestamibi scintigraphy and CT combination. Combination of all three modalities showed a sensitivity of 95.4% ⁶. 4-D CT has higher sensitivity of 88% for precise localization of abnormal parathyroid glands compared with ultrasound or scintigraphy ⁶⁷. ¹⁸F-fluoromethylcholine PET/CT is useful for ectopic and small gland localization and has higher accuracy of 96.3% than ultrasound and scintigraphy ⁶⁸.

On basis of the data reviewed two different algorithms can be proposed for localization, in first time operations and re-operative cases. In de novo cases ultrasound is the main and also the first line examination, followed by sestamibi scintigraphy or CT. Overall, 4-DCT has superior performance than sestamibi scintigraphy. Yet in most centers sestamibi scintigraphy is more commonly used second line modality, due to its availability and radiation exposure considerations in younger patients with 4-D CT ¹⁰. In re-operative cases imaging depends upon modalities used in initial work-up. First line modalities used in re-operative cases include both ultrasound and 4-D CT. Sestamibi scintigraphy is usually not used in recurrent or persistent cases. However, first line imaging is usually negative or discordant in re-operative cases. In such cases PET/CT or MRI are preferred prior to attempting invasive localization ¹¹. Even though the emerging techniques, 4-D CT, PET/CT and PET/MR have shown promising results yet they are not widely available and require larger sample size to prove their beneficial role ⁶⁹.

Limitations Possible limitation of this review is that pre-operative localization can be most accurate only when each technique is performed by an expert radiologist. Correlation between imaging techniques used and surgical outcome can help propose definite algorithm in first operations as well as re-operative cases. Accuracy of pre-operative localization largely depends on local practices, techniques available in different centers and radiologic expertise. Large sample size is required for PET/CT, 4-D CT and MRI to develop beneficial role. Non-availability of high-performance techniques in institutions is a limiting factor to correctly determine their accuracy. Large scale prospective studies need to be conducted.

CONCLUSIONS

Pre-operative localization of parathyroid glands in primary hyperparathyroidism using different imaging techniques permits targeted evaluation of abnormal tissue. Technique, accuracy, advantages and disadvantages of non-invasive modalities are reviewed in this article. However, a single algorithm cannot be devised due to variation in practice, availability of techniques and patient population in different institutions. When used in concert the aforementioned and discussed techniques enable surgeons to perform targeted tissue dissection with improved surgical outcome.

ARTICLE INFORMATION

Accepted for Publication: March 14, 2020
Published Online: March 30, 2020.

<https://doi.org/10.48111/2020.01.05>

Open Access: This is an open access article distributed under the terms of the CC-BY License. © 2020 Ashraf et al ASR.

Author Affiliations: Department of Surgery, Shalamar Medical & Dental College, Lahore, Pakistan (Ashraf, Shafiq, Ahmed, Waseem)

Author Contributions:

Conceptualization: Ashraf; Waseem, Ahmed
Data curation: Ashraf; Shafiq; Waseem
Formal analysis: Ashraf; Waseem, Ahmed
Funding acquisition: Ashraf
Investigation, Methodology: Ashraf; Waseem
Project administration: Waseem; Ashraf
Resources, Software, Supervision: Shafiq; Ashraf; Waseem
Roles/Writing - original draft; Writing - review & editing: Ashraf; Shafiq; Waseem

Financial Support and Sponsorship: Nil.

Conflicts of Interest: There are no conflicts of interest

REFERENCES

- Fraser WD. Hyperparathyroidism. *The Lancet*. 2009;374(9684):145-158. doi:10.1016/S0140-6736(09)60507-9
- Yeh MW, Ituarte PHG, Zhou HC, et al. Incidence and Prevalence of Primary Hyperparathyroidism in a Racially Mixed Population. *The Journal of Clinical Endocrinology & Metabolism*. 2013;98(3):1122-1129. doi:10.1210/jc.2012-4022
- Ruda JM, Hollenbeak CS, Stack BC. A systematic review of the diagnosis and treatment of primary hyperparathyroidism from 1995 to 2003. *Otolaryngology - Head and Neck Surgery*. 2005;132(3):359-372. doi:10.1016/j.otohns.2004.10.005
- Wilhelm SM, Wang TS, Ruan DT, et al. The American association of endocrine surgeons guidelines for definitive management of primary hyperparathyroidism. *JAMA Surgery*. 2016;151(10):959-968. doi:10.1001/jamasurg.2016.2310
- Scattergood S, Marsden M, Kyrimi E, et al. Combined ultrasound and Sestamibi scintigraphy provides accurate preoperative localisation for patients with primary hyperparathyroidism. *The Annals of The Royal College of Surgeons of England*. 2019;101(2):97-102. doi:10.1308/rcsann.2018.0158
- Baj J, Sitarz R, Łokaj M, et al. Preoperative and Intraoperative Methods of Parathyroid Gland Localization and the Diagnosis of Parathyroid Adenomas. *Molecules*. 2020;25(7):1724. doi:10.3390/molecules25071724
- Wang CA. The anatomic basis of parathyroid surgery. *Annals of Surgery*. 1976;183(3):271-275. doi:10.1097/00000658-197603000-00010
- Peissig K, Condie BG, Manley NR. Embryology of the Parathyroid Glands. *Endocrinology and Metabolism Clinics of North America*. 2018;47(4):733-742. doi:10.1016/j.ecl.2018.07.002
- Minisola S, Cipriani C, Diacinti D, et al. Imaging of the parathyroid glands in primary hyperparathyroidism. *European Journal of Endocrinology*. 2016;174(1):D1-D8. doi:10.1530/EJE-15-0565
- Bunch PM, Kelly HR. Preoperative Imaging Techniques in Primary Hyperparathyroidism: A Review. *JAMA Otolaryngology - Head and Neck Surgery*. 2018;144(10):929-937. doi:10.1001/jamaoto.2018.1671
- Parikh AM, Grogan RH, Morón FE. Localization of Parathyroid Disease in Reoperative Patients with Primary Hyperparathyroidism. *International Journal of Endocrinology*. 2020;2020. doi:10.1155/2020/9649564
- Vitetta GM, Neri P, Chiecchio A, et al. Role of ultrasonography in the management of patients with primary hyperparathyroidism: Retrospective comparison with technetium-99m sestamibi scintigraphy. *Journal of Ultrasound*. 2014;17(1):1-12. doi:10.1007/s40477-014-0067-8
- Liddy S, Worsley D, Torreggiani W, et al. Preoperative Imaging in Primary Hyperparathyroidism: Literature Review and Recommendations. *Canadian Association of Radiologists Journal*. 2017;68(1):47-55. doi:10.1016/j.carj.2016.07.004
- Kuzminski SJ, Sosa JA, Hoang JK. Update in Parathyroid Imaging. *Magnetic Resonance Imaging Clinics of North America*. 2018;26(1):151-166. doi:10.1016/j.mric.2017.08.009
- Reeder SB, Desser TS, Weigel RJ, et al. Sonography in Primary Hyperparathyroidism. *Journal of Ultrasound in Medicine*. 2002;21(5):539-552. doi:10.7863/jum.2002.21.5.539
- Kunstman JW, Kirsch JD, Mahajan A, et al. Parathyroid Localization and Implications for Clinical Management. *The Journal of Clinical Endocrinology & Metabolism*. 2013;98(3):902-912. doi:10.1210/jc.2012-3168
- Cheung K, Wang TS, Farrokhyar F, et al. A meta-analysis of preoperative localization techniques for patients with primary hyperparathyroidism. *Annals of Surgical Oncology*. 2012;19(2):577-583. doi:10.1245/s10434-011-1870-5
- Lee JB, Kim WY, Lee YM. The role of preoperative ultrasonography, computed tomography, and sestamibi scintigraphy localization in secondary hyperparathyroidism. *Annals of Surgical Treatment and Research*. 2015;89(6):300-305. doi:10.4174/ast.2015.89.6.300
- Aghaa A, Hornung M, Schlitt HJ, et al. The role of contrast-enhanced ultrasonography (CEUS) in comparison with 99mTechnetium-sestamibi scintigraphy for localization diagnostic of primary hyperparathyroidism. *Clinical Hemorheology and Microcirculation*. 2014;58(4):515-520. doi:10.3233/CH-131800
- Lubitz CC, Hunter GJ, Hamberg LM, et al. Accuracy of 4-dimensional computed

- tomography in poorly localized patients with primary hyperparathyroidism. *Surgery*. 2010;148(6):1129-1138. doi:10.1016/j.surg.2010.09.002
21. Richards ML, Thompson GB, Farley DR, et al. Reoperative parathyroidectomy in 228 patients during the era of minimal-access surgery and intraoperative parathyroid hormone monitoring. *American Journal of Surgery*. 2008;196(6):937-943. doi:10.1016/j.amjsurg.2008.07.022
 22. Hindié E, Ugur Ö, Fuster D, et al. 2009 EANM parathyroid guidelines. *European Journal of Nuclear Medicine and Molecular Imaging*. 2009;36(7):1201-1216. doi:10.1007/s00259-009-1131-z
 23. Mortenson MM, Evans DB, Lee JE, et al. Parathyroid Exploration in the Reoperative Neck: Improved Preoperative Localization with 4D-Computed Tomography. *Journal of the American College of Surgeons*. 2008;206(5):888-895. doi:10.1016/j.jamcollsurg.2007.12.044
 24. Sinha P, Oates ME. Parathyroid scintigraphy: How does it fit in? *Radiology*. 2019;291(2):477-478. doi:10.1148/radiol.2019190304
 25. Eslamy HK, Ziessman HA. Parathyroid scintigraphy in patients with primary hyperparathyroidism: 99mTc sestamibi SPECT and SPECT/CT. *Radiographics*. 2008;28(5):1461-1476. doi:10.1148/rg.285075055
 26. Carpentier A, Jeannette S, Verreault J, et al. Preoperative localization of parathyroid lesions in hyperparathyroidism: Relationship between technetium-99m-MIBI uptake and oxyphil cell content. *Journal of Nuclear Medicine*. 1998;39(8 SUPPL.):1441-1444. Accessed August 24, 2020. <https://europepmc.org/article/med/9708524>
 27. Caveny SA, Klingensmith WC, Martin WE, et al. Parathyroid imaging: The importance of dual-radiopharmaceutical simultaneous acquisition with 99mTc-Sestamibi and T231. *Journal of Nuclear Medicine Technology*. 2012;40(2):104-110. doi:10.2967/jnmt.111.098400
 28. Greenspan BS, Dillehay G, Intenno C, et al. SNM practice guideline for parathyroid scintigraphy 4.0. *Journal of Nuclear Medicine Technology*. 2012;40(2):111-118. doi:10.2967/jnmt.112.105122
 29. Wei WJ, Shen CT, Song HJ, et al. Comparison of SPET/CT, SPET and planar imaging using 99mTc-MIBI as independent techniques to support minimally invasive parathyroidectomy in primary hyperparathyroidism: A meta-analysis. *Hellenic Journal of Nuclear Medicine*. 2015;18(2):127-135. doi:10.1967/s002449910207
 30. Chen C, Skarulis M, Fraker DL, et al. Technetium-99m-sestamibi imaging before reoperation for primary hyperparathyroidism. *The Journal of nuclear medicine (1978)*. 1995;36(12).
 31. Yen TWF, Wang TS, Doffek KM, et al. Reoperative parathyroidectomy: An algorithm for imaging and monitoring of intraoperative parathyroid hormone levels that results in a successful focused approach. *Surgery*. 2008;144(4):611-621. doi:10.1016/j.surg.2008.06.017
 32. García-Talavera San Miguel P, Gómez-Camínero López F, Villanueva Curto JG, et al. Update of the role of Nuclear Medicine techniques in the pre-surgical localization of primary hyperparathyroidism. *Revista Española de Medicina Nuclear e Imagen Molecular (English Edition)*. 2019;38(2):123-135. doi:10.1016/j.remnie.2019.01.006
 33. Friedman K, Somervell H, Patel P, et al. Effect of calcium channel blockers on the sensitivity of preoperative 99mTc-MIBI SPECT for hyperparathyroidism. *Surgery*. 2004;136(6):1199-1204. doi:10.1016/j.surg.2004.06.047
 34. Mehmet Uludağ. Preoperative Localization Studies in Primary Hyperparathyroidism. Published online 2019. doi:10.14744/SEMB.2019.78476
 35. Hoang JK, Williams K, Gaillard F, et al. Parathyroid 4D-CT: Multi-institutional International Survey of Use and Trends. *Otolaryngology - Head and Neck Surgery (United States)*. 2016;155(6):956-960. doi:10.1177/0194599816655311
 36. Gafton AR, Glastonbury CM, Eastwood JD, et al. Parathyroid lesions: Characterization with dual-phase arterial and venous enhanced CT of the neck. *American Journal of Neuroradiology*. 2012;33(5):949-952. doi:10.3174/ajnr.A2885
 37. Hunter GJ, Ginat DT, Kelly HR, et al. Discriminating Parathyroid Adenoma from Local Mimics by Using Inherent Tissue Attenuation and Vascular Information Obtained with Four-Dimensional CT: Formulation of a Multinomial Logistic Regression Model. *Radiology*. 2014;270(1):168-175. doi:10.1148/radiol.13122851
 38. Eichhorn-Wharry LI, Carlin AM, Talpos GB. Mild hypercalcemia: An indication to select 4-dimensional computed tomography scan for preoperative localization of parathyroid adenomas. *American Journal of Surgery*. 2011;201(3):334-338. doi:10.1016/j.amjsurg.2010.08.033
 39. Suh YJ, Choi JY, Kim SJ, et al. Comparison of 4D CT, Ultrasonography, and 99mTc Sestamibi SPECT/CT in Localizing Single-Gland Primary Hyperparathyroidism. *Otolaryngology-Head and Neck Surgery*. 2015;152(3):438-443. doi:10.1177/0194599814562195
 40. Day KM, Elsayed M, Beland MD, et al. The utility of 4-dimensional computed tomography for preoperative localization of primary hyperparathyroidism in patients not localized by sestamibi or ultrasonography. *Surgery (United States)*. 2015;157(3):534-539. doi:10.1016/j.surg.2014.11.010
 41. Ramirez AG, Shada AL, Martin AN, et al. Clinical efficacy of 2-phase versus 4-phase computed tomography for localization in primary hyperparathyroidism. *Surgery (United States)*. 2016;160(3):731-737. doi:10.1016/j.surg.2016.04.016
 42. Hamidi M, Sullivan M, Hunter G, et al. 4D-CT is Superior to Ultrasound and Sestamibi for Localizing Recurrent Parathyroid Disease. *Annals of Surgical Oncology*. 2018;25(5):1403-1409. doi:10.1245/s10434-018-6367-z
 43. Sho S, Yilma M, Yeh MW, et al. Prospective validation of two 4D-CT-based scoring systems for prediction of multigland disease in primary hyperparathyroidism. *American Journal of Neuroradiology*. 2016;37(12):2323-2327. doi:10.3174/ajnr.A4948
 44. Chazen JL, Gupta A, Dunning A, et al. Diagnostic accuracy of 4D-CT for parathyroid adenomas and hyperplasia. *American Journal of Neuroradiology*. 2012;33(3):429-433. doi:10.3174/ajnr.A2805
 45. Galvin L, Oldan JD, Bahl M, et al. Parathyroid 4D CT and Scintigraphy: What Factors Contribute to Missed Parathyroid Lesions? *Otolaryngology - Head and Neck Surgery (United States)*. 2016;154(5):847-853. doi:10.1177/0194599816630711
 46. Kelly HR, Hamberg LM, Hunter GJ. 4D-CT for preoperative localization of abnormal parathyroid glands in patients with hyperparathyroidism: Accuracy and ability to stratify patients by unilateral versus bilateral disease in surgery-naïve and re-exploration patients. *American Journal of Neuroradiology*. 2014;35(1):176-181. doi:10.3174/ajnr.A3615
 47. Hinson AM, Lee DR, Hobbs BA, et al. Preoperative 4D CT Localization of Nonlocalizing Parathyroid Adenomas by Ultrasound and SPECT-CT. *Otolaryngology - Head and Neck Surgery (United States)*. 2015;153(5):775-778. doi:10.1177/0194599815599372
 48. Beland MD, Mayo-Smith WW, Grand DJ, et al. Dynamic MDCT for Localization of Occult Parathyroid Adenomas in 26 Patients With Primary Hyperparathyroidism. *American Journal of Roentgenology*. 2011;196(1):61-65. doi:10.2214/AJR.10.4459
 49. Kluijfhout WP, Venkatesh S, Beninato T, et al. Performance of magnetic resonance imaging in the evaluation of first-time and reoperative primary hyperparathyroidism. *Surgery (United States)*. 2016;160(3):747-754. doi:10.1016/j.surg.2016.05.003
 50. Nael K, Hur J, Bauer A, et al. Dynamic 4D MRI for characterization of parathyroid adenomas: Multiparametric analysis. *American Journal of Neuroradiology*. 2015;36(11):2147-2152. doi:10.3174/ajnr.A4425
 51. Gotway MB, Reddy GP, Webb WR, et al. Comparison between MR imaging and 99mTc MIBI scintigraphy in the evaluation of recurrent or persistent hyperparathyroidism. *Radiology*. 2001;218(3):783-790. doi:10.1148/radiology.218.3.r01fe38783
 52. Argirò R, Diacinti D, Sacconi B, et al. Diagnostic accuracy of 3T magnetic resonance imaging in the preoperative localisation of parathyroid adenomas: comparison with ultrasound and 99mTc-sestamibi scans. *European Radiology*. 2018;28(11):4900-4908. doi:10.1007/s00330-018-5437-8
 53. Brewer HB, Fairwell T, Ronan R, et al. Human parathyroid hormone: amino-acid sequence of the amino-terminal residues 1-34. *Proceedings of the National Academy of Sciences of the United States of America*. 1972;69(12):3585-3588. doi:10.1073/pnas.69.12.3585
 54. Hara T. 18F-Fluorocholine: A New Oncologic PET Tracer. *JNM*. 2001;42(12):1815-1817. Accessed August 24, 2020. <http://jnm.snmjournals.org/content/42/12/1815>

55. Kluijfhout WP, Pasternak JD, Drake FT, et al. Use of PET tracers for parathyroid localization: a systematic review and meta-analysis. *Langenbeck's Archives of Surgery*. 2016;401(7):925-935. doi:10.1007/s00423-016-1425-0
56. Hessman O, Stålberg P, Sundin A, et al. High success rate of parathyroid reoperation may be achieved with improved localization diagnosis. *World Journal of Surgery*. 2008;32(5):774-781. doi:10.1007/s00268-008-9537-5
57. Otto D, Boerner AR, Hofmann M, et al. Pre-operative localisation of hyperfunctional parathyroid tissue with ¹¹C-methionine PET. *European Journal of Nuclear Medicine and Molecular Imaging*. 2004;31(10):1405-1412. doi:10.1007/s00259-004-1610-1
58. Sundin A, Hellman P, Ahlström H. *Image Analysis of Arteries in MR Angiography View Project*; 1996. Accessed August 24, 2020. <https://www.researchgate.net/publication/14290281>
59. Neumann DR; ECBJr; MWJ; et al. Regional Body FDG-PET in Postoperative Recurrent Hyperparath... : Journal of Computer Assisted Tomography. *JCAT*. 1997;21(1):25-28. Accessed August 24, 2020. https://journals.lww.com/jcat/Abstract/1997/01000/Regional_Body_FDG_PET_in_Postoperati ve_Recurrent.5.aspx
60. Traub-Weidinger T, Mayerhoefer ME, Koperek O, et al. ¹¹C-Methionine PET/CT Imaging of ^{99m}Tc-MIBI-SPECT/CT-Negative Patients With Primary Hyperparathyroidism and Previous Neck Surgery. *The Journal of Clinical Endocrinology & Metabolism*. 2014;99(11):4199-4205. doi:10.1210/jc.2014-1267
61. Amadou C, Bera G, Ezziane M, et al. 18F-Fluorocholine PET/CT and Parathyroid 4D Computed Tomography for Primary Hyperparathyroidism: The Challenge of Reoperative Patients. *World Journal of Surgery*. 2019;43(5):1232-1242. doi:10.1007/s00268-019-04910-6
62. Grimaldi S, Young J, Kamenicky P, et al. Challenging pre-surgical localization of hyperfunctioning parathyroid glands in primary hyperparathyroidism: the added value of 18F-Fluorocholine PET/CT. *European Journal of Nuclear Medicine and Molecular Imaging*. 2018;45(10):1772-1780. doi:10.1007/s00259-018-4018-z
63. Broos WAM, van der Zant FM, Knol RJJ, et al. Choline PET/CT in parathyroid imaging: a systematic review. *Nuclear Medicine Communications*. 2019;40(2):96-105. doi:10.1097/MNM.0000000000000952
64. Thanseer NTK, Parihar A, Sood A, et al. Evaluation of recurrent parathyroid carcinoma: A new imaging tool in uncommon entity. *World Journal of Nuclear Medicine*. 2019;18(2):198. doi:10.4103/wjnm.wjnm_67_18
65. Rep S, Hocevar M, Vaupotic J, et al. 18F-choline PET/CT for parathyroid scintigraphy: Significantly lower radiation exposure of patients in comparison to conventional nuclear medicine imaging approaches. *Journal of Radiological Protection*. 2018;38(1):343-356. doi:10.1088/1361-6498/aaa86f
66. Hocevar M, Lezica L, Rep S, et al. Focused parathyroidectomy without intraoperative parathormone testing is safe after pre-operative localization with 18F-Fluorocholine PET/CT. *European Journal of Surgical Oncology*. 2017;43(1):133-137. doi:10.1016/j.ejso.2016.09.016
67. Rodgers SE, Hunter GJ, Hamberg LM, et al. Improved preoperative planning for directed parathyroidectomy with 4-dimensional computed tomography. *Surgery*. 2006;140(6):932-941. doi:10.1016/j.surg.2006.07.028
68. Thanseer N, Bhadada SK, Sood A, et al. Comparative Effectiveness of Ultrasonography, ^{99m}Tc-Sestamibi, and 18F-Fluorocholine PET/CT in Detecting Parathyroid Adenomas in Patients With Primary Hyperparathyroidism. *Clinical Nuclear Medicine*. 2017;42(12):e491-e497. doi:10.1097/RLU.0000000000001845
69. Wojtczak B, Syrycka J, Kaliszewski K, et al. Surgical implications of recent modalities for parathyroid imaging. *Gland Surgery*. 2020;9(Suppl 2):S86-S94. doi:10.21037/gs.2019.11.10